

CONSENSUS STATEMENT

European consensus for the management of patients with differentiated thyroid carcinoma of the follicular epithelium

Furio Pacini, Martin Schlumberger¹, Henning Dralle², Rossella Elisei³, Johannes W A Smit⁴, Wilmar Wiersinga⁵ and the European Thyroid Cancer Taskforce

Section of Endocrinology and Metabolism, University of Siena, Via Bracci, 53100 Siena, Italy, ¹Service de Médecine Nucléaire, Institut Gustave Roussy, Villejuif, France, ²Department of General, Visceral and Vascular Surgery, University of Halle, Germany, ³Department of Endocrinology, University of Pisa, Italy, ⁴Department of Endocrinology and Metabolic Disease, Leiden University Medical Center, The Netherlands and ⁵Department of Endocrinology and Metabolism, University of Amsterdam, The Netherlands

(Correspondence should be addressed to F Pacini; Email: pacini8@unisi.it)

Introduction

Thyroid carcinoma is rare among human malignancies (<1%) but is the most frequent endocrine cancer, accounting for about 5% of thyroid nodules (1). The latter are very frequent in the general population and, according to the method of detection and the age of the patients, their prevalence may approach 20–50% of the general population, thus representing a daily issue in endocrine clinics. Furthermore, the incidence of thyroid cancer, mainly differentiated, is one of the most rapidly increasing human cancers, at least in the United States (2), with the papillary histotype being the most frequent (nearly 80%). There is a need for uniform diagnostic and treatment strategies for thyroid nodules and differentiated thyroid cancer (DTC) since the disease requires a multidisciplinary approach, including endocrinology, internal medicine, nuclear medicine, oncology, endocrine (general or head and throat) surgery and even general practice operating in different settings not always equipped with the appropriate services (such as specialized centers, general hospitals and peripheral centers). Not infrequently among European countries, epidemiology may differ according to different environment, probably reflecting different clinical practice or pathogenetic factors, which may change the presentation and the management strategy. In addition, in recent decades, the clinical presentation of differentiated thyroid cancer has been changing from advanced cases requiring intense treatment and surveillance to cancers detected by fortuitous neck ultrasonography (US) requiring less aggressive treatment and follow-up. Diagnostic and treatment tools have also improved in recent years (sensitive assays for serum thyroglobulin measurement, neck US, recombinant human thyrotropin (rhTSH)), thus allowing for less invasive and uncomfortable procedures for the patients. Altogether, these considerations dictate the need for applying the more effective, less invasive and less expensive procedures able to guarantee the best management and the best quality of life for a disease that, albeit having an intrinsic low mortality, requires life-long follow-up care.

Several European countries have developed their own guidelines or consensus reports (3–6), based on consolidated experience and cultural attitude of the country. Nevertheless, they differ in several, sometimes important, aspects. Following the spirit of concrete cultural and scientific integration among the countries participating in the new reality of the European Union, the European Thyroid Association (ETA) has endorsed the implementation of this consensus for the management of thyroid nodules and DTC.

Actions

For the implementation of the consensus, the ETA and ETA-cancer research network (CRN) approached the National Endocrine Societies in Europe requesting the appointment of two thyroid cancer experts for each country. Twenty five countries answered positively and appointed a total of 50 experts who created a taskforce with two coordinators for the development of the consensus. They identified the most relevant diagnostic and therapeutic issues as listed below:

- pre-surgical evaluation of thyroid nodules;
- surgical treatment;
- tumor-node-metastasis (TNM) and other prognostic systems;
- postsurgical administration of radioiodine;
- follow-up: role of diagnostic whole body scan (WBS), role of thyroglobulin (Tg), anti-Tg antibodies (AbTg) and neck US;
- protocols for early and long-term follow-up;
- treatment of local and regional recurrences and of distant metastases.

These issues were discussed in a meeting that took place in Athens on 24 May 2005. The experts were advised to base their statements on clinical and scientific evidence whenever available in the current literature. The first session of the meeting was devoted to presentations on the state of the art for each selected issue, followed by an extensive discussion. In the second session, the experts

were divided into four subgroups whose aim was to concur on different issues, which were then reported to the whole group of experts. During the following months the coordinators drafted a text that was circulated among the members of the taskforce and the discussion took place via electronic mail up to the delivery of the final text. Although the primary aim was to set up consensus statements for DTC, we felt that a brief presentation on the management of thyroid nodules was also needed.

Thyroid nodules

Evaluation of thyroid nodules

Thyroid nodules do not reflect a single disease but are the clinical manifestation of a wide spectrum of different thyroid diseases (7). In a normal gland or a diffuse goiter, thyroid nodules may be solitary or multiple (8). Among multinodular goiters, one nodule may become clinically dominant in terms of growth, dimension, and functional characteristic. The risk of malignancy is similar among hypofunctioning solitary nodules and multinodular goiter. Non-tumoral nodules may be found in patients with thyroid hyperplasia, and with inflammatory or autoimmune thyroid diseases. The aim of the diagnostic approach to thyroid nodules is the differential diagnosis between benign and malignant nodules and, in the event of malignancy, the selection of an appropriate surgical procedure (Fig. 1).

The first step after the discovery of a thyroid nodule is to perform a complete history and physical examination of the thyroid and the neck. Finding suggestive of malignancy are history of familial thyroid cancer, of exposure to radiation during childhood and of rapid growth, hoarseness, hard and irregular consistency, ipsilateral cervical lymphadenopathy and fixation of the nodule to extrathyroidal tissues.

Neck ultrasonography and thyroid scintigraphy

Currently, thyroid US is the most accurate imaging technique for the detection of thyroid nodules and this procedure is mandatory when a nodule is discovered at palpation (9). US can accurately identify the features and the size of the dominant nodule and of additional non-palpable nodules, particularly in the context of a multinodular goiter. US is also a guide to fine needle aspiration cytology (FNAC) (9, 10). In addition, neck US is able to detect suspicious cervical lymph nodes as small as a few millimeters in diameter.

Ultrasonographic features suggestive of malignant thyroid nodules are the following: hypoechogenicity, microcalcifications, absence of peripheral halo, irregular borders, intranodular hypervascularity and regional lymphadenopathy. A combination of these

ultrasonographic findings might have a high predictive value for malignancy (11).

Although the advent of thyroid US has limited the use of the thyroid scan, this test is still useful to confirm the functioning nature of a nodule when the serum thyrotropin (TSH) is low or undetectable and in patients with multinodular goiter, because it frequently demonstrates the presence of autonomous functioning nodules (7).

Fine needle aspiration cytology

Any solitary thyroid nodule (≥ 1 cm) should be submitted to cytology unless proven to be hyperfunctioning with low-suppressed serum TSH. Micronodules (< 1 cm) carry a very low risk of morbidity even if malignant and should be submitted to FNAC only in the event of suspicious finding at US (solid hypoechoic with microcalcifications) or personal history. In the case of multinodular goiter, FNAC should be performed in the dominant nodules, guided by the results of US and the thyroid scan.

FNAC is the gold standard for differential diagnosis, although there are limitations: inadequate samples and follicular neoplasia (9, 10, 12). In all cases, the sensitivity of the method depends largely on the experience of the cytologist reading the slides and the methodology of sample collection and smear staining. In the event of inadequate samples, FNAC is repeated (13). In the case of follicular neoplasia, after excluding the hyperfunctioning nature of the nodule by TSH measurement and confirmatory thyroid scan (hot nodule), no other test can distinguish the benign or malignant nature of the nodule. Immunocytochemistry with claimed markers of malignancy is neither sensitive nor specific enough and such techniques should be validated before routine use. The correct diagnosis can be obtained only at histology (14, 15). The surgical procedure for follicular neoplasia should consist of lobectomy in the case of a solitary nodule or near-total thyroidectomy in the case of multinodular goiter. Frozen section examination may be performed, but many authors do not perform this procedure in view of the high frequency of false negative results (14). These authors suggest near-total thyroidectomy in the case of follicular neoplasm associated with clinical suspicion of malignancy or when the patient's preference is to undergo radical surgery directly rather than take the risk of two-stage surgery in the event of malignancy found at postoperative histology (16).

When cytology is definitely positive or even leads to suspicion of papillary thyroid carcinoma, total (or near-total) thyroidectomy is the recommended surgical procedure. In the case of suspicious papillary thyroid carcinoma, some centers perform a lobectomy with frozen section examination; however, since the rate of false positive results of a cytology suspicious for papillary thyroid cancer is very low (about 2%) and the rate of false negative frozen section may be high (about 40%), many

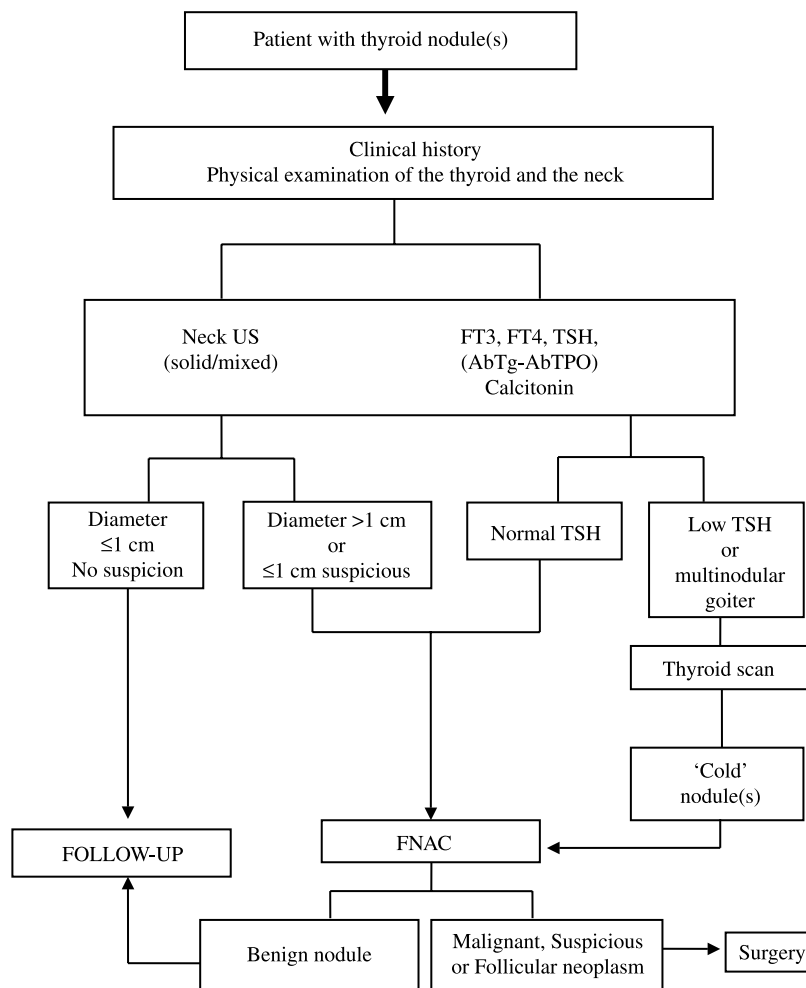


Figure 1 Flow chart for the diagnostic evaluation of thyroid nodule(s). US, ultrasonography; FT3, free triiodothyronine; FT4, free thyroxine; TSH, thyrotropin; AbTg, anti-thyroglobulin antibodies; AbTPO, antithyroidperoxidase antibodies; FNAC, fine needle aspiration cytology.

centers advocate total (or near-total) thyroidectomy in all cases (17). The issue of lymph node surgery is considered in the section entitled ‘Surgery’.

Laboratory evaluation

Measurement of serum TSH (preferably associated with free thyroxine (FT4) and free triiodothyronine (FT3)) is indicated at the first visit of the patient to rule out the presence of underlying thyroid disorders (hypo- and hyperthyroidism).

Measurements of thyroid autoantibodies (particularly anti-antibodies thyroid peroxidase (AbTPO)) are useful for the detection of autoimmune thyroiditis but their contribution to the differential diagnosis of thyroid nodules is poor.

Measurement of serum Tg has no role in the diagnostic evaluation of thyroid nodules, since its concentration is

correlated with the size rather than with the nature of the nodule or of the thyroid gland (18).

Measurement of serum calcitonin (Ct) in patients with thyroid nodules: elevated levels of serum Ct are almost synonymous with medullary thyroid cancer, once the few conditions leading to moderately elevated serum Ct (renal failure, rare ectopic Ct production from non-thyroidal neuro-endocrine tumors, hypergastrinemia, Hashimoto’ thyroiditis (controversial), interference from heterophylic antibodies) have been ruled out. Several European prospective studies of unselected thyroid nodules have demonstrated that routine measurement of serum Ct allows the detection of unsuspected medullary thyroid carcinoma with a frequency of 1 in 200–300 thyroid nodules, with better sensitivity than FNAC, and that routine Ct screening improves the outcome. Thus, serum Ct measurement is recommended in the initial diagnostic evaluation of thyroid nodules (19–22).

Differentiated thyroid cancer

Preoperative staging

Papillary thyroid carcinoma presents with cervical lymph node metastases in nearly 50% of patients, with a frequency increasing with the size and the extrathyroidal extension of the primary tumor. For this reason, surgery must be preceded by an ultrasonographic evaluation of the lymph node chains. In case of suspicion, the metastatic nature of a lump is easily confirmed by FNAC, with the measurement of Tg in the wash-out of the needle employed for aspiration (23).

Other imaging techniques, such as computed tomography (CT), magnetic resonance (MR) and positron emission tomography (PET) scan, are not indicated as routine procedures, but may be required in selected patients with clinical evidence of local extension or of distant metastases. Laryngo-tracheoscopy and esophageal endoscopy are indicated in the presence of locally aggressive cancers with signs or symptoms of extrathyroidal invasion.

When radiologic imaging using iodine-containing contrast media has been used, any subsequent radioiodine scintigraphy or treatment must be delayed for 2–3 months.

Surgical treatment

Surgery for thyroid cancer should be performed by experienced surgeons embedded in multidisciplinary teams trained specifically in thyroid cancer surgery and operating on a large number of thyroid cancer patients annually, including both primary as well as reoperative cases. Patients undergoing operations for thyroid nodules should undergo FNAC to avoid completion thyroidectomy due to postoperative incidental detection of thyroid carcinoma. The aim of intraoperative frozen section is similar, but its value in detecting minimally invasive follicular cancer or a follicular variant of papillary thyroid cancer is very limited.

Apart from solitary well differentiated thyroid cancer less than 1 cm in diameter with no evidence for nodal or distant metastases, and no history of previous radiation exposure that may be operated on by less than total thyroidectomy, the standard surgical treatment is total (or near-total) thyroidectomy. This procedure decreases the risk of local recurrence and is performed with almost no morbidity under expert hands. Moreover, it facilitates postsurgical radioiodine ablation and adequate follow-up (16, 24–28). More limited thyroidectomy should not be performed, and if a patient is referred after less than near-total thyroidectomy, completion thyroidectomy should be proposed in the case of a large tumor, multifocality, extrathyroidal extension and/or vascular invasion evidence of local or distant metastases, previous history of radiation exposure or unfavorable histology (29–31). In cases of primary tumors between

10 and 20 mm in diameter that have been diagnosed at postoperative definite histopathology, the indication for completion thyroidectomy should be discussed with the patient on the basis of the risks and benefits of reoperative surgery, including the potential risk of surgical morbidity. Depending on the size of the thyroid remnant, an effective alternative to completion thyroidectomy when the risk of persistent disease is low may be radioiodine ablation of the residual thyroid tissue (32).

Compartment-oriented microdissection of lymph nodes should be performed in cases of preoperative suspected and/or intraoperatively proven lymph node metastases (33). The rationale for this surgical approach is based on evidence that radical primary surgery has a favorable impact on survival in high-risk patients, and on the recurrence rate in low-risk patients (34–36).

The benefits of prophylactic 'en bloc' central node dissection in the absence of pre- or intraoperative evidence for nodal disease are controversial. There is no evidence that it improves recurrence or mortality rates, but it permits an accurate staging of the disease that may guide subsequent treatment and follow-up.

Invasion of the cervicovisceral axis is rarely observed in DTC. However, owing to its potential life-threatening complications and the limited non-operative treatment alternatives, surgical resection should be taken into consideration in the absence of progressive distant disease (37). The indication for surgery depends not only on local resectability but also on the individual patient's condition. Depending on the extent of invasion, the surgical strategy may range from simple trachea wall ('window') resection to complex laryngo-tracheal and esophageal procedures.

Children and adolescents should be treated with the same surgical procedure as adults, provided they are treated by an experienced surgeon. In this case the rate of complications is no different from that of adults.

Surgical complications: laryngeal nerve palsy.

Depending on the size of the primary tumor, permanent paralysis is rare (<2%) when the patient is treated by an experienced surgeon (38). Transient vocal dysfunction is more frequent but resolves spontaneously in most patients within 1–6 months. Much higher rates of complications are observed when surgery is undertaken by non-dedicated surgeons. After surgery, all patients with voice changes should be referred to a specialist for laryngoscopy.

When it occurs, permanent unilateral recurrent laryngeal nerve paralysis (RLNP) is frequently well tolerated, but rarely may be life threatening by inducing aspiration pneumonia. Permanent unilateral RLNP may decrease quality of life by decreasing voice quality and by increasing vocal effort. Simple surgical techniques have been developed to treat the deleterious effects of RLNP by lateralization of the paralyzed vocal

fold. These techniques have a low complication rate and are highly efficient (39).

Surgical complications: hypoparathyroidism. After total thyroidectomy with or without parathyroid transplantation, hypocalcemia occurs in one third of cases, but persists longer than 3 months in less than 2% (38). Symptoms of hypocalcemia should be noted and total serum calcium, preferably ionized calcium, should be checked the day after surgery, and daily until stable. Follow-up should include ionized calcium. Serum parathyroid hormone (PTH) measurement may be useful in borderline cases to predict the possibility of recovery from hypocalcemia.

If hypocalcemia develops or the patient becomes symptomatic, calcium supplementation should be commenced, together with alfacalcidol or other vitamin D derivatives. Close monitoring of serum calcium is needed to prevent hypercalcemia.

Postsurgical radioiodine administration (thyroid ablation)

Rationale. Thyroid ablation refers to the postsurgical administration of ¹³¹I, whose aim is to destroy any thyroid residue in the thyroid bed (16, 40–41). Its use is based on the following assumptions:

1. ¹³¹I treatment of residual postoperative microscopic tumor foci may decrease the recurrence rate and possibly the mortality rate (40–43).
2. ¹³¹I ablation of residual normal thyroid tissue facilitates the early detection of recurrence based on serum Tg measurement and eventually on ¹³¹I WBS.
3. A high activity of ¹³¹I permits a highly sensitive post-therapy WBS, 2–5 days after its administration, and this may reveal previously undiagnosed tumors.

Indications. Three groups of patients can be individualized according to the surgeon’s and pathologist’s reports (44) (Table 1):

- *Very low-risk group.* Patients with unifocal microcarcinoma (≤1 cm) with no extension beyond the thyroid capsule and without lymph node metastases. Consensus: no benefits, no indication for postoperative ¹³¹I administration
- *High-risk group.* Patients with documented persistent disease or at high risk of persistent or recurrent disease. Consensus: postoperative ¹³¹I administration reduces the recurrence rate and possibly prolongs survival; it also permits early detection of persistent disease. A high activity of radioiodine is indicated, following prolonged withdrawal of thyroid hormone treatment, since the use of rhTSH has not yet been approved for this indication.
- *Low-risk group.* Includes all other patients. No consensus: benefits are controversial and there are still uncertainties as to whether it should be administered to all patients or only to selected patients. Many clinicians perform ablation in this setting where completeness of thyroidectomy is uncertain; there is no consensus on when surgery has been complete because in this setting benefits are not demonstrated. Whether a low or a high activity should be administered and whether preparation should be achieved by prolonged withdrawal or following rhTSH stimulation are still uncertain and need further studies.

Preparation and procedure. The patient should be seen by a nuclear medicine specialist or endocrinologist, preferably in a combined clinic, for assessment and full discussion about rationale, side-effects, procedure and radioprotection during the stay in the center and after

Table 1 Indications for postsurgical thyroid ablation (risk stratification).

No indication (low risk of relapse or cancer-specific mortality)	Definite indication (use high activity (≥3.7 GBq (100 mCi)) after thyroid hormone withdrawal)	Probable indication (use high or low activity (3.7 or 1.1 GBq (100 or 30 mCi)))
Complete surgery Favorable histology Unifocal T ≤1 cm, N0, M0 No extrathyroidal extension	Distant metastases or Incomplete tumor resection or Complete tumor resection but high risk for recurrence or mortality: tumor extension beyond the thyroid capsule (T3 or T4) or lymph node involvement	Less than total thyroidectomy or No lymph node dissection or Age <18 years or T1 >1 cm and T2, N0 M0 Or unfavorable histology: Papillary: tall-cell, columnar-cell, diffuse sclerosing Follicular: widely invasive or poorly differentiated

discharge. Written information and support from a specialist nurse should be provided.

Recommendations:

- Radioiodine therapy must be given only in centers suitably equipped for the purpose.
- Effective thyroid ablation requires adequate stimulation by TSH. Two methods of preparation are available: thyroid hormone withdrawal and consequent hypothyroidism, or administration of rhTSH (Thyrogen, Genzyme Transgenics Corporation, Cambridge, MA) with the patient continuing l-thyroxine (LT4) therapy, thus preserving quality of life (45).
- Thyroid hormone withdrawal: LT4 treatment is withdrawn for 4–5 weeks. Alternatively, to reduce symptoms of hypothyroidism, patients may switch from T4 to T3 replacement for 3 weeks and then T3 is withdrawn for 2 weeks. Serum TSH should be measured prior to ¹³¹I administration and be above an empirically determined level (> 30 mU/l) (46).
- Successful thyroid ablation has been reported after preparation by rhTSH using ¹³¹I activity determined by individual dosimetry (47), and more recently after a fixed dose of 3700 MBq (100 mCi) (48). The latter procedure was approved in 2005 in Europe by the European Medicines Agency (EMA) for the preparation to the administration of 3700 MBq to low-risk patients. When using rhTSH, the patient should receive one i.m. injection of 0.9 mg rhTSH on 2 consecutive days and receive radioiodine 24 h after the second injection.
- The value of a diagnostic scan before thyroid ablation has been questioned based on its low clinical utility, the possibility of a stunning effect on the subsequent therapeutic activity of ¹³¹I, and the consideration that the post-therapy WBS performed 3–5 days after radioiodine administration is much more sensitive than the diagnostic WBS (49–51). Thus, this procedure may be avoided without loss of information. Centers may choose to perform a pre-ablation scan in some circumstances, such as uncertainty concerning the extent of thyroidectomy. In such cases, ¹²³I or a low activity of ¹³¹I (3.7 MBq, 100 µCi) should be used in order to reduce stunning. Large thyroid remnants may require further surgery or the use of corticosteroids to limit radiation thyroiditis.
- Serum Tg should be measured immediately before ¹³¹I administration in the case of withdrawal or on the third day after the second injection in the case of preparation with rhTSH. Low Tg levels in this setting are associated with a favorable outcome
- Pregnancy must be excluded before ¹³¹I therapy is given.
- A low-iodine diet should be advised for a period of 3 weeks before ¹³¹I administration; iodine excess should be excluded. In case of doubt, or preferably

as a routine procedure, urinary iodine excretion should be measured (53). In the event of iodine contamination (e.g. contrast media), radioiodine administration should be postponed for 2–3 months.

- The administered ¹³¹I activity among centers ranges between 1110 MBq (30 mCi) (low activity) and 3700 MBq (100 mCi) or even more (high activity).
- A post-ablation WBS is performed 3–5 days after the administration of ¹³¹I. It is highly informative when uptake in thyroid remnants is <2% of the administered activity (53, 54).
- Total body retention or external radiation dose rate should be measured before discharge of the patient, to ensure that regulatory criteria for radioprotection are met.
- If the patient has been prepared by thyroid hormone withdrawal, LT4 medication is resumed on the second or third day after ¹³¹I administration.

Pathological and clinical staging after initial treatment

Conventionally, staging of DTC is based on the pathological assessment with the addition of information derived from the postsurgical ¹³¹I WBS, if this is performed within 3 months of thyroidectomy. Post-operative staging allows risk stratification of individual patients, which in turn will dictate the frequency and type of follow-up (16, 55–60). In most staging systems, but not all (58, 61), age is considered an independent risk factor.

Several prognostic scoring systems have been developed by authoritative centers. The most popular is the American joint committee on cancer/International union against cancer TNM staging system based mainly on the extent of the tumor and age, and the use of this system is advocated by this panel (Table 2) (62). It should be noted that in the absence of routine lymph node dissection, patients should be quoted NX and cannot be accurately stratified.

In accordance with this system, the panel agreed to group patients into three risk categories at the time of initial treatment:

- very low risk: unifocal T1 (≤1 cm) NOM0 and no extension beyond the thyroid capsule;
- low risk: T1 (>1 cm) NOM0 or T2NOM0 or multifocal T1NOM0;
- high risk: any T3 and T4 or any T, N1 or any M1.

Thyrotropin-suppressive therapy

Rationale and recommendation:

- The role of TSH-suppressive therapy after initial treatment is twofold: the first aim is to correct the

Table 2 TNM and staging classification of thyroid carcinoma of the follicular epithelium: comparison of the 5th and 6th editions of Ref. 62.

5th edition	6th edition
TNM	Summary of changes
	<ul style="list-style-type: none"> • Tumor staging (T) has been revised and the categories redefined • T4 is now divided into T4a and T4b • Nodal staging (N) has been revised • All anaplastic carcinomas are considered T4. The T4 category for anaplastic carcinomas is divided into T4a (intra-thyroidal anaplastic carcinoma – surgically resectable) and T4b (extra-thyroidal anaplastic carcinoma – surgically unresectable) • For papillary and follicular carcinomas, the stage grouping for patients older than 45 has been revised. Stage III includes tumors with minimal extra-thyroid extension. Stage IVA includes tumors of any size extending beyond the thyroid capsule to invade subcutaneous soft tissues, larynx, trachea, esophagus, OR recurrent laryngeal nerve. Stage IVB includes tumors that invade prevertebral fascia, carotid artery, or mediastinal vessels. Stage IVC includes advanced tumors with distant metastasis
T0 – No evidence of primary tumor	T0 – No evidence of primary tumor
T1 – tumor 1 cm or less in greatest dimension limited to the thyroid	T1 – tumor 2 cm or less in greatest dimension limited to the thyroid (<i>Supplementum to the 6th edition: T1a-tumor 1 cm or less, T1b-tumor more than 1 cm but not more than 2 cm</i>)
T2 – tumor more than 1 cm, but not more than 4 cm, in greatest dimension limited to the thyroid	T2 – tumor more than 2 cm, but not more than 4 cm, in greatest dimension limited to the thyroid
T3 – tumor more than 4 cm in greatest dimension limited to the thyroid	T3 – tumor more than 4 cm in greatest dimension limited to the thyroid or any tumor with minimal extra-thyroid extension (e.g. extension to sternothyroid muscle or perithyroid soft tissues)
T4 – tumor of any size extending beyond the thyroid capsule	T4 – excluded
T4a – excluded	T4a – tumor of any size extending beyond the thyroid capsule to invade subcutaneous soft tissues, larynx, trachea, esophagus, or recurrent laryngeal nerve
T4b – excluded	T4b – tumor invades prevertebral fascia or encases carotid artery or mediastinal vessels. All anaplastic carcinomas are considered T4 tumors
	T4a – intra-thyroidal anaplastic carcinoma – surgically resectable
	T4b – extra-thyroidal anaplastic carcinoma – surgically unresectable
Regional lymph nodes are the cervical and upper mediastinal lymph nodes	Regional lymph nodes are the central compartment, lateral cervical, and upper mediastinal lymph nodes
NX – regional lymph nodes cannot be assessed	NX – regional lymph nodes cannot be assessed
N0 – no regional lymph node metastases	N0 – no regional lymph node metastases
N1 – regional lymph node metastases	N1 – regional lymph node metastases
N1a – metastasis in ipsilateral cervical lymph node(s)	N1a – metastasis to Level VI (pretracheal, paratracheal, and prelaryngeal/Delphian lymph nodes)
N1b – metastasis in bilateral, midline, or contralateral cervical or mediastinal lymph node(s)	N1b – metastasis to unilateral, bilateral, or contralateral cervical or superior mediastinal lymph nodes
Distant metastases	Distant metastases
MX – distant metastasis cannot be assessed	MX – distant metastasis cannot be assessed
M0 – no distant metastasis	M0 – no distant metastasis
M1 – distant metastasis	M1 – distant metastasis
Staging	Staging
Separate stage groupings are recommended for papillary, follicular, medullary, or undifferentiated (anaplastic) carcinoma	Separate stage groupings are recommended for papillary or follicular, medullary, and anaplastic (undifferentiated) carcinoma

Diagnostic tools for follow-up after initial treatment

Physical examination and neck ultrasonography.

Physical examination is not very sensitive for the detection of persistent or recurrent disease in the neck.

Neck US is an operator-dependent procedure, and a 'learning curve' may improve individual performance. It is more sensitive than neck palpation and is used routinely for assessing lymph node chains as well as the thyroid bed. It can detect lymph nodes as small as 2–3 mm in diameter. Benign lymph node hyperplasia is frequent. For a lymph node larger than 5 mm in its smaller diameter that persists over several months, specificity of neck US is improved by studying its US characteristics and by performing US-guided FNAC for cytology and Tg measurement in the aspirate fluid. Any suspicious lymph node smaller than 5 mm in diameter only needs explicit description and periodical monitoring by US, and reassurance of the patient.

Serum Tg determination. Tg is a specific and extremely useful tumor marker for follow-up of patients with papillary and follicular thyroid carcinoma.

Serum Tg should be measured using a sensitive IRMA assay (functional sensitivity <1.0 ng/ml) standardized on the European reference standard (CRM 457) (69, 70). When using such methods, the presence of anti-Tg antibodies in the circulation may interfere with the assay, leading to false negative serum Tg determination. Thus, the presence of anti-Tg antibodies must be ruled out by direct measurement of anti-Tg antibodies, in preference to the Tg recovery test. Anti-Tg antibodies will decrease and disappear in patients in complete remission, although the time elapsing between the disappearance of the antigen and of the antibody may take 2–3 years (71). Thus, the persistence or reappearance of circulating anti-Tg antibodies may be regarded as an 'indicator' of disease. Tg is produced by both normal and neoplastic thyroid cells and its production is under TSH control. Serum TSH should always be measured at the time of Tg determination.

In very low-risk patients, not submitted to radioiodine ablation, the risk of persistent/recurrent disease is by definition very low, and TSH stimulation, either by thyroid hormone withdrawal or rhTSH administration, is usually not recommended. Follow-up is based on serum Tg determination during LT4 treatment plus neck US.

After total thyroid ablation by surgery and radioiodine, the Tg level should be undetectable and any detectable level should alert the clinician (72, 73). Radioiodine ablation improves the specificity of serum Tg determination; in these patients TSH stimulation improves its sensitivity without decreasing its specificity.

The rare false negative serum Tg determinations following TSH stimulation are due mainly to small lymph node metastases that are demonstrated by neck US (74, 75).

The stimulated Tg level is usually lower following rhTSH than after withdrawal (76). A sensitive Tg assay should be used and any detectable serum level should be taken into account, because the individual concentration of Tg cannot discriminate between the presence of residual normal thyroid cells, local disease or distant metastases.

Serum Tg may remain detectable for some months after surgery or radioiodine treatment. Thus, serum Tg should not be measured less than 3 months after initial treatment. Both the level and the trend of serum Tg in consecutive determinations should be taken into account.

Supersensitive Tg assays have a higher sensitivity but at the expense of a much lower specificity, so they are not currently recommended for routine use.

To ensure continuity in monitoring, clinicians should use the same Tg assay on a long-term basis. Laboratories should run internal and external quality controls for serum Tg and should not change methods without prior consultation with the clinical users.

Management of Tg positive, scan negative patients. In patients with elevated Tg levels after endogenous or exogenous TSH stimulation or rising Tg on consecutive determinations in the same metabolic condition (on LT4 or following TSH stimulation) and no other evidence of disease, a WBS performed 3–5 days after administration of a large activity of radioiodine may identify previously undetected neoplastic foci. Identification of the site of Tg production may dictate appropriate treatment modalities (surgery in the case of lymph node metastases or a single resectable distant lesion) (77–79).

Serum Tg may remain detectable for some months after initial treatment, and a large activity of ^{131}I should be administered only in patients with Tg levels above a given cut-off value and with an increasing trend.

In patients with negative post-treatment WBS, administration of high-activity ^{131}I should not be repeated. Other diagnostic imaging procedures should be performed, including CT scanning, MRI or fluoro-deoxy-D-glucose (FDG)-PET scanning.

Management of patients with positive AbTg. As mentioned above, in patients with positive levels of AbTg, undetectable serum Tg levels cannot be interpreted as evidence of remission. These patients must be monitored with periodical ^{131}I diagnostic WBS and neck US. Whenever there is a suspicion of distant disease, patients should also undergo imaging techniques such as CT, MRI, and FDG-PET. The disappearance of AbTg

during follow-up may in itself be considered as evidence of remission (71).

Role of diagnostic ^{131}I whole body scan. TSH stimulation is obtained with prolonged thyroid hormone withdrawal or with rhTSH injections.

An activity of 74–185 MBq (2–5 mCi) ^{131}I is administered, with a WBS performed 2 or 3 days later. It is preferable that a double-headed gamma camera, equipped with high-energy collimators and thick crystal, is used. Scanning should be performed at low speed (6–8 cm/min, for at least 30 min or 140 000 counts), with spot images on any suspicious area of uptake.

In patients with small thyroid remnants, the postsurgical WBS performed with a large activity is more sensitive than the diagnostic scan performed during the subsequent follow-up with lower activity; ablation (no visible uptake or, if visible, <0.1% and undetectable serum Tg) is achieved in almost all these patients. A diagnostic WBS will demonstrate foci of uptake outside the thyroid bed only in patients with detectable serum Tg levels following TSH stimulation. In addition, cervical node metastases are best seen by neck US. Thus, if there is no evidence of persistent disease, a diagnostic control WBS is usually not indicated.

At present, the best definition of successful ablation is an undetectable serum Tg level following TSH stimulation and normal neck US (66).

TSH stimulation. TSH stimulation increases Tg production by thyroid cells and thus increases the sensitivity of serum Tg determination for the detection of persistent or recurrent disease. ^{131}I uptake is low or absent during TSH suppression, and TSH stimulation should be performed before any administration of ^{131}I for diagnosis or therapy.

TSH stimulation can be achieved by two alternative methods:

1. Thyroid hormone withdrawal: LT4 treatment is withdrawn for 4–5 weeks. To reduce symptoms of hypothyroidism, patients may switch from T4 to T3 for 3 weeks and then T3 is withdrawn for 2 weeks. Serum TSH should be measured prior to ^{131}I administration and be above an empirically determined level (>30 mU/l). Rare circumstances in which the patient cannot elicit a sustained release of endogenous TSH include hypothalamic or pituitary dysfunction, long-term corticosteroid administration and an unusually slow response, particularly in the elderly (80).
2. rhTSH injections: rhTSH (0.9 mg) is injected i.m. for 2 consecutive days (days 1 and 2) and ^{131}I is administered on the day after the second injection (day 3). Serum Tg is measured on the third day after the second injection (day 5) (81). rhTSH provides a stimulation that is similarly efficient to withdrawal for

diagnostic purposes, with the exception of a few sporadic patients with metastatic thyroid carcinomas not stimulated by rh TSH but detected after endogenous TSH elevation (82). Adverse effects are rare, minor and transient, comprising nausea, fatigue and headache. No serious toxicity has so far been reported, and no anti-TSH antibodies have been found following rhTSH injections. Its advantages are that it avoids hypothyroidism, retains quality of life, decreases the risk of morbidity associated with withdrawal, and avoids prolonged absence from work. Its cost is well balanced by these advantages (45).

3. Patients unable to raise endogenous TSH, or for whom prolonged withdrawal is contraindicated or poorly tolerated, should undergo rhTSH stimulation as preparation for treatment. In patients with spinal cord compression or brain metastases, a short course of high-dose corticosteroids will avoid worsening of neurological symptoms.

Other procedures. Complementary imaging modalities include CT scan of the neck and lungs, and MRI of bones and brain. Bone scintigraphy is poorly sensitive.

FDG-PET scan is rarely indicated in these patients. It is useful to detect neoplastic foci located in the posterior neck or mediastinum in patients with an elevated serum Tg without radioiodine uptake. It may also be performed before any aggressive treatment procedure to ensure the absence of other neoplastic foci. Its sensitivity may be improved by TSH stimulation. Finally, high FDG uptake in large tumor masses may have an unfavorable prognostic significance (83–87).

When FDG-PET is available, there is little or no indication for scintigraphy with other non-specific radioactive tracers.

Follow-up protocol soon after initial treatment (Fig. 2)

If the WBS performed a few days after the postsurgical administration of radioiodine shows small thyroid remnants and no uptake outside the thyroid bed, patients are seen at 3 months (on LT4 treatment) for serum TSH and Tg determinations.

At 6–12 months, disease status is assessed by physical examination, neck US, and serum Tg determination obtained 3 days after the second injection of rhTSH. Thyroid hormone withdrawal should be used only when rhTSH is not available or not affordable.

Low-risk patients with normal US and an undetectable serum Tg following rhTSH are considered cured, as subsequent recurrences are very rare (<1% at 10 years). Diagnostic WBS is indicated by some authors in high-risk patients or

when the post-ablation WBS was poorly informative due to high uptake in thyroid remnants or when it disclosed suspicious uptake. Suspicious findings at neck US should be submitted to further testing: either repeat US some months later if ≤ 5 mm, or US-guided FNAC if > 5 mm in its smaller diameter (or with suspicious findings at US) (66, 88–90).

Patients with detectable serum Tg following rhTSH stimulation in the range of 1–2 ng/ml should be submitted to an additional Tg stimulation test with rhTSH 12 months later. If serum Tg becomes undetectable, the patient is considered cured. If serum Tg increases above its previous level, recurrent disease should be sought by performing a CT scan of the neck and chest and the administration of a therapeutic activity of ^{131}I .

Very low-risk patients, eventually treated with lobectomy, are followed periodically by neck US and serum Tg measurement on LT4 treatment.

Long-term follow-up

In low-risk patients with no evidence of disease at the 9–12 month assessment, the LT4 dose is decreased, with the goal of obtaining a TSH level within the lower normal range (65). In patients initially considered at high risk it may be safer to maintain the serum TSH at a low level for 3–5 years. Even in these patients, the risk of recurrence is low when there is no evidence of disease and they can be reclassified as low risk.

Follow-up comprises serum TSH and Tg determinations on LT4 treatment together with a physical examination, on a yearly basis, provided there is no evidence of disease. Neck US is performed either routinely or only in patients with suspicious clinical findings.

Whether control of Tg following rhTSH stimulation may be useful at 3–5 years requires confirmation. Follow-up should be continued throughout life. This is performed either in a specialized center or by an outside specialist, depending on the local collaborative network.

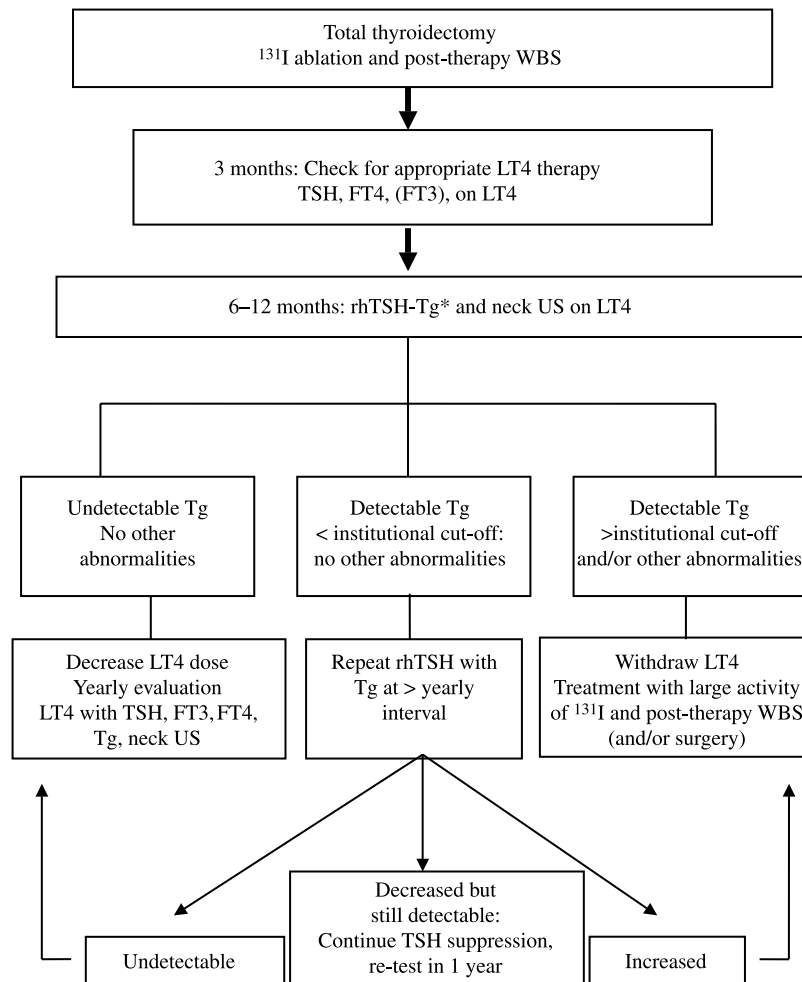


Figure 2 Flow chart for the follow-up after initial treatment (surgery and radioiodine ablation). *If basal Tg is detectable there is no need for rhTSH stimulation and the patient needs imaging and/or therapy.

Management of patients with recurrent or metastatic disease

Remission can be obtained in about two thirds of patients with neck recurrence and in one third of those with distant metastases. Remission is more frequently achieved in patients with a limited tumor burden (91–94).

Local and regional recurrence. Treatment is based on the combination of surgery and ^{131}I , in those with ^{131}I uptake. The use of an intraoperative probe may improve the success rate of surgery.

When complete surgical excision is not possible, external beam radiotherapy may be indicated if there is no significant radioiodine uptake within the tumor.

Distant metastases. Lung metastases. In the case of ^{131}I uptake, treatment consists of ^{131}I administration following prolonged withdrawal. An activity ranging between 3.7 and 7.4 GBq (or higher) is administered every 4–8 months during the first 2 years and thereafter at longer intervals (91–94).

A WBS performed 2–5 days after administration of ^{131}I provides assessment of response to treatment, together with serum Tg monitoring, thus guiding further treatment. Diagnostic ^{131}I WBS is not required prior to treatment, because it will not modify the indication for treatment and may induce stunning (reduction of uptake of the subsequent therapeutic activity).

There is no maximum limit for the cumulative ^{131}I activity that can be given to patients with persistent disease. However, most remissions are obtained with cumulative activity equal to or lower than 22 GBq (600 mCi); above this cumulative activity the indication for further treatments should be taken on an individual basis.

Lithium may be a useful adjuvant for radioiodine therapy of metastatic well-differentiated thyroid carcinomas, increasing both the accumulation and retention of radioiodine in lesions (95, 96).

Bone metastases. Bone metastases should be treated by a combination of surgery whenever possible, ^{131}I treatment if uptake is present in the metastases, and external beam radiotherapy either as resolutive treatment or as pain control (97–100). Other local treatment procedures such as the use of bisphosphonates, embolization or cement injection may be useful.

Brain metastases. Brain metastases are relatively rare. Whenever possible they should be resected; if not resectable and non-iodine-avid, external beam radiation may provide palliation. Usually they carry a poor prognosis (101).

Harmful effects of radioiodine

Possible early effects. Radiation thyroiditis with swelling and discomfort is more frequent in patients with large thyroid remnants and can be limited by the use of corticosteroids for a few days. Abnormalities of taste and smell are frequent but transient. Nausea and vomiting can be minimized by anti-emetic drugs. Sialadenitis can be limited by liberal hydration and by lemon juice given 24 h after radioiodine (102, 103). A single ablation activity rarely leads to xerostomia. Dry eye is also infrequent. Radiation exposure of the bladder (and gonads) may be limited by liberal hydration, and colon exposure by laxative treatment (104).

Hypospermia has been observed following ^{131}I treatment but is usually transient (105). Pre-treatment sperm banking should be offered to male patients if multiple activities of ^{131}I are planned. Conception should not occur before a minimum of 4 months after ^{131}I treatment as this allows for the life span of a sperm cell. In women, if conception is deferred for at least 6 months after ^{131}I treatment, there is no increased risk of abnormal pregnancy outcome, although the risk of miscarriage is slightly increased if pregnancy occurs between 6 and 12 months after treatment (106). Breast feeding should be discontinued before ^{131}I is given. An earlier onset of menopause has been reported after repeated courses of radioiodine (107).

Possible late effects. A significantly increased risk of leukemia and secondary cancers has been reported in patients treated with high cumulative activities of radioiodine (>22 GBq; 600 mCi). For this reason, ^{131}I should be given only when benefits are expected, and in these patients the minimal activity should be administered (108, 109).

Radiation fibrosis can occur in patients with diffuse pulmonary metastases who received repeated activities of radioiodine over short intervals of time.

Role of external beam radiotherapy

External beam radiotherapy to the neck is used infrequently. Radiotherapy should be planned carefully, with precautions taken for prevention of radiation myelopathy. For microscopic residual disease it should deliver a total dose of 50–60 Gy to the neck and upper mediastinum, in 25–30 sessions with five sessions per week. A boost of 5–10 Gy may then be given to any gross residual neoplastic focus. It is indicated as initial treatment or for recurrence of unresectable tumors or local invasion presumed to have macro- or microscopic residual disease, which does not concentrate ^{131}I . External beam radiotherapy may also be indicated for bone or brain metastases (110, 111).

Role of cytotoxic chemotherapy and experimental therapies

Cytotoxic chemotherapy has no role in routine management of papillary and follicular thyroid cancer. Its use is restricted to patients with progressive disease uncontrolled by surgery, ¹³¹I or other treatment modalities. Response is poor, at best 10–20% with single-agent doxorubicin or the combination of doxorubicin–cisplatin. In any case, responses are partial and transient with no prolongation of survival (112–114). Interestingly, the response rate of poorly differentiated thyroid carcinomas to chemotherapy in the setting of an elevated serum TSH (endogenous or exogenous) has been shown to be improved, but needs confirmatory trials (115).

Molecular targeted therapies and anti-angiogenic agents are being studied in prospective controlled trials and may represent hope for such patients (116).

Acknowledgements

This consensus report is endorsed by the European Thyroid Association (ETA) and the ETA-Cancer Research Network (ETA-CRN). European Thyroid Cancer Taskforce (by country of appointment): *Belgium*: Moreno-Reyes R (Brussels); *Van den Bruel A* (Leuven), *Cyprus*: Zira C (Nicosia), *Denmark*: Feldt-Rasmussen U (Copenhagen); *Godballe C* (Odense), *France*: Corone C (Saint Cloud); *Borson-Charzot F* (Bron), *Germany*: Reiners C (Wuerzburg), *Greece*: Alevizaki M (Athens); *Duntas L* (Athens); *Vlassopoulou B* (Athens), *Hungary*: Esik O (Pecs); *Mezosi E* (Pecs), *Ireland*: Moriarty M J (Dublin); *Smyth P* (Dublin), *Israel*: Cohen O (Tel-Hashomer); *Krausz Y* (Jerusalem), *Italy*: Pellegriti G (Catania); *Castagna M G* (Siena), *Latvia*: Marga M (Riga), *Norway*: Bioro T (Oslo), *Poland*: Jarzab B (Gliwice), *Portugal*: Carrilho F (Coimbra); *de Castro J J* (Lisbon); *Limbert E S* (Lisbon), *Romania*: Ioachim D (Bucharest); *Mogos V* (Iasi); *Ursu H* (Bucharest), *Russian Federation*: Roumiantsev P (Obnisk); *Troshina E* (Moscow), *Slovakia*: Hnilica P (Bratislava), *Slovenia*: Besic N (Ljubjana); *Zagar I* (Ljubjana), *Spain*: Gomez J M (Barcelona); *Sanchez-Franco F* (Madrid), *Sweden*: Berg G (Gotenburg); *Tennvall J* (Lund); *Wallin G K* (Stockholm), *Switzerland*: Meier C A (Geneve), *The Netherlands*: Links T P (Groningen), *Turkey*: Ayvaz G (Ankara); *Uysal A R* (Ankara), *Ukraine*: Cherenko S (Kiev); *Larin O* (Kiev), *United Kingdom*: Harmer C (London).

References

- Coleman PM, Babb P, Damiecky P, Grosclaude P, Honjo S, Jones J, Knerer G, Pitard A, Quinn M, Sloggett A & De Stavola B. *Cancer Survival Trends in England and Wales 1971–1995: Deprivation and NHS Region Series SMPS no. 61*, pp. 471–478. London: Stationery Office, 1999.
- Hodgson NC, Button J & Solorzano CC. Thyroid cancer: is the incidence still increasing? *Annals of Surgical Oncology* 2004 **11** 1093–1097.
- Guidelines for the Management of Thyroid Cancer in Adults*. Ed. Publication Unit of the Royal College of Physicians, London: British Thyroid Association and Royal College of Physicians, 2002.
- Rodrigues FJC, Limbert ES, Marques AP, Santos AP, Lopes C, Rodrigues E, Borges F, Carrilho FM, de Castro JJ, Neto JMA, Salgado L & Oliveira MJ. Thyroid Study Group. Protocol for the treatment and follow-up of differentiated follicular thyroid carcinomas. *Portuguese Medical Minutes* 2005 **18**.
- Trattamento e Follow-up del Carcinoma Tiroideo Differenziato della Tiroide*. Linee Guida SIE-AIMN-AIFM, pp 1–75, 2004.
- Van De Velde CJH, Hamming JF, Goslings BM, Schelfout LJD, Clark OH, Smeds A, Bruining HA, Krenning P & Cady B. Report of the consensus development conference on the management of differentiated thyroid cancer in The Netherlands. *European Journal of Cancer and Clinical Oncology* 1988 **24** 287–292.
- Pacini F, Burrioni L, Ciului C, Di Cairano G & Guarino E. Management of thyroid nodules: a clinicopathological, evidence-based approach. *European Journal of Nuclear Medicine and Molecular Imaging* 2004 **31** 1443–1449.
- Belfiore A, La Rosa GL, La Porta GA, Giuffrida D, Milazzo G, Lupo L, Regalboto C & Vigneri R. Cancer risk in patients with cold thyroid nodules: relevance of iodine uptake, sex, age, and multinodularity. *American Journal of Medicine* 1992 **93** 363–369.
- Marqusee E, Benson CB, Frates MC, Doubilet PM, Larsen PR, Cibas ES & Mandel SJ. Usefulness of ultrasonography in the management of nodular thyroid disease. *Annals of Internal Medicine* 2000 **133** 696–700.
- Frates MC, Benson CB, Charboneau JW, Cibas ES, Clark OH, Coleman BG, Cronan JJ, Doubilet PM, Evans DB, Goellner JR, Hay ID, Hertzberg BS, Intenzo CM, Jeffrey RB, Langer JE, Larsen PR, Mandel SJ, Middleton WD, Reading CC, Sherman SI & Tessler FN Society of Radiologists in Ultrasound. Management of thyroid nodules detected at US: Society of Radiologists in Ultrasound consensus conference statement. *Radiology* 2005 **237** 794–800.
- Hegedus L. Thyroid ultrasound. *Endocrinology and Metabolism Clinics of North America* 2001 **30** 339–360.
- Cap J, Riska A, Rehorkova P, Hovorkova E, Kerekes Z & Pohnetalova D. Sensitivity and specificity of the fine needle aspiration biopsy of the thyroid: clinical point of view. *Clinical Endocrinology* 1999 **51** 509–515.
- Braga M, Cavalcanti TC, Collaco LM & Graf H. Efficacy of ultrasound-guided fine-needle aspiration biopsy in the diagnosis of complex thyroid nodules. *Journal of Clinical Endocrinology and Metabolism* 2001 **86** 4089–4091.
- Mulcahy MM, Cohen JL, Anderson PE, Ditamasso J & Schmidt W. Relative accuracy of fine-needle aspiration and frozen section in the diagnosis of well-differentiated thyroid cancer. *Laryngoscope* 1998 **104** 494–496.
- Giuffrida D & Gharib H. Anaplastic thyroid cancer: current diagnosis and treatment. *Annals of Oncology* 2000 **11** 1083–1089.
- Mazzaferri EL & Jhiang SM. Long term impact of initial surgical and medical therapy on papillary and follicular thyroid cancer. *American Journal of Medicine* 1994 **49** 418–428.
- Goldstein RE, Netterville JL, Burkey B & Johnson JE. Implications of follicular neoplasms, atypia, and lesions suspicious for malignancy diagnosed by fine-needle aspiration of thyroid nodules. *Annals of Surgery* 2002 **235** 656–662; discussion 662–664.
- Guarino E, Tarantini B, Pilli T, Checchi S, Brilli L, Ciului C, Di Cairano G, Mazzucato P & Pacini F. Presurgical serum thyroglobulin has no prognostic value in papillary thyroid cancer. *Thyroid* 2005 **15** 1041–1045.
- Elisei R, Bottici V, Luchetti F, Di Coscio G, Romei C, Grasso L, Miccoli P, Iacconi P, Basolo F, Pinchera A & Pacini F. Impact of routine measurement of serum calcitonin on the diagnosis and

- outcome of medullary thyroid cancer: experience in 10,864 patients with nodular thyroid disorders. *Journal of Clinical Endocrinology and Metabolism* 2004 **89** 163–168.
- 20 Niccoli P, Wion-Barbot N, Caron P, Henry JF, de Micco C, Saint Andre JP, Bigorgne JC, Modigliani E & Conte-Devolx B. Interest of routine measurement of serum calcitonin: study in a large series of thyroidectomized patients. The French Medullary Study Group. *Journal of Clinical Endocrinology and Metabolism* 1997 **82** 338–341.
 - 21 Rieu M, Lame MC, Richard A, Lissak B, Sambort B, Vuong-Ngoc P, Berrod JL & Fombour JP. CT prevalence of sporadic medullary thyroid carcinoma: the importance of routine measurement of serum calcitonin in the diagnostic evaluation of thyroid nodules. *Clinical Endocrinology (Oxford)* 1995 **42** 453–460.
 - 22 Vierhapper H, Raber W, Bieglmayer C, Kaserer K, Weinhausl A & Niederle B. Routine measurement of plasma calcitonin in nodular thyroid diseases. *Journal of Clinical Endocrinology and Metabolism* 1997 **82** 1589–1593.
 - 23 Shimamoto K, Satake H, Sawaki A, Ishigaki T, Funahashi H & Imai T. Preoperative staging of thyroid papillary carcinoma with ultrasonography. *European Journal of Radiology* 1998 **29** 4–10.
 - 24 Esnaola NF, Cantor SB, Sherman SI, Le JE & Evans DB. Optimal treatment strategy in patients with papillary thyroid cancer: a decision analysis. *Surgery* 2001 **130** 921–930.
 - 25 Hay ID, Bergstralh EJ, Goellner JR, Ebersold JR & Grant CS. Predicting outcome in papillary thyroid carcinoma: development of a reliable prognostic scoring system in a cohort of 1779 patients surgically treated at one institution during 1940 through 1989. *Surgery* 1993 **114** 1050–1058.
 - 26 Hay ID, Grant CS, Bergstralh EJ, Thompson GB, van Heerden JA & Goellner JR. Unilateral total lobectomy: is it sufficient surgical treatment for patients with AMES low-risk papillary thyroid carcinoma? *Surgery* 1998 **124** 958–966.
 - 27 Hundahl SA, Cady B, Cunningham MP, Mazzaferri E, McKee RF, Rosai J, Shah JP, Fremgen AM, Stewart AK & Hölzer S. Initial results from a prospective cohort study of 5583 cases of thyroid carcinoma treated in the United States during 1996. *Cancer* 2000 **89** 202–217.
 - 28 Machens A, Holzhausen HJ & Dralle H. The prognostic value of primary tumor size in papillary and follicular thyroid carcinoma. *Cancer* 2005 **103** 2269–2273.
 - 29 Gardner RE, Tuttle RM, Burman KD, Haddady S, Truman C, Sparling YH, Wartofsky L, Sessions RB & Ringel MD. Prognostic importance of vascular invasion in papillary thyroid carcinoma. *Archives of Otolaryngology – Head and Neck Surgery* 2000 **126** 309–312.
 - 30 Pacini F, Elisei R, Capezzone M, Miccoli P, Molinaro E, Basolo F, Agate L, Bottici V, Raffaelli M & Pinchera A. Contralateral papillary thyroid cancer is frequent at completion thyroidectomy with no difference in low- and high-risk patients. *Thyroid* 2001 **11** 877–881.
 - 31 Machens A, Hinze R, Lautenschläger C, Thomusch O & Dralle H. Prophylactic completion thyroidectomy for differentiated thyroid carcinoma: prediction of extrathyroidal soft tissue infiltrates. *Thyroid* 2001 **11** 381–384.
 - 32 Randolph GW & Daniels GH. Radioactive iodine lobe ablation as an alternative to completion thyroidectomy for follicular carcinoma of the thyroid. *Thyroid* 2002 **12** 989–996.
 - 33 Ito Y, Tomoda C, Uruno T, Takamura Y, Miya A, Kobayashi K, Matsuzuka F, Kuma K & Miyauchi A. Preoperative ultrasonographic examination for lymph node metastases: usefulness when designing lymph node dissection for papillary microcarcinoma of the thyroid. *World Journal of Surgery* 2004 **28** 498–501.
 - 34 Machens A, Hinze R, Thomusch O & Dralle H. Pattern of nodal metastasis for primary and reoperative thyroid cancer. *World Journal of Surgery* 2002 **26** 22–28.
 - 35 Scheumann GF, Gimm O, Wegener G, Hundeshagen H & Dralle H. Prognostic significance and surgical management of locoregional lymph node metastases in papillary thyroid cancer. *World Journal of Surgery* 1994 **18** 559–568.
 - 36 Tisell LE, Nilsson B, Molne J, Hansson G, Fyalling M, Janson S & Wingren U. Improved survival of patients with papillary thyroid cancer after surgical microdissection. *World Journal of Surgery* 1996 **20** 854–859.
 - 37 Dralle H, Brauckhoff M, Machens A & Gimm O. Surgical management of advanced thyroid cancer invading the aerodigestive tract. In *Textbook of Endocrine Surgery*, 2nd edn, pp 318–333. Eds OH Clark, QY Duh & E Kebebew. Philadelphia: Elsevier Saunders, 2005.
 - 38 Thomusch O, Sekulla C, Walls G, Fasshauer M & Dralle H. Analysis of surgery-related complications in thyroid carcinoma – a German prospective multi-centre study with 275 patients. *Acta Chirurgica Austriaca* 2001 **33** 194–198.
 - 39 Hartl DM, Travagli JP, Lebouleux S, Baudin E, Brasnu DF & Schlumberger M. Current concepts in the management of unilateral recurrent laryngeal nerve paralysis after thyroid surgery. *Journal of Clinical Endocrinology and Metabolism* 2005 **90** 3084–3088.
 - 40 Samaan NA, Schultz PN, Hickey RC, Goepfert H, Haynie TP, Johnston DA & Ordenez NG. The results of various modalities of treatment of well differentiated thyroid carcinomas: a retrospective review of 1599 patients. *Journal of Clinical Endocrinology and Metabolism* 1992 **75** 714–720.
 - 41 Mazzaferri EL & Jhiang SM. Differentiated thyroid cancer: long-term impact of initial therapy. *Transactions of the American Clinical and Climatological Association* 1994 **106** 151–168; discussion 168–170.
 - 42 Taylor T, Specker B, Robbins J, Sperlin M, Ho M, Ain K, Bigos ST, Brierly J, Cooper D, Haughen B, Hay I, Hertzberg V, Klein I, Ladenson P, Nishiyama R, Ross D, Sherman S & Maxon HR. Outcome after treatment of high-risk papillary and non-Hurthle-cell follicular thyroid carcinoma. *Annals of Internal Medicine* 1998 **129** 622–627.
 - 43 Sawka AM, Thephamongkhon K, Brouwers M, Thabane L, Browman G & Gerstein HC. Clinical review 170: a systematic review and metaanalysis of the effectiveness of radioactive iodine remnant ablation for well-differentiated thyroid cancer. *Journal of Clinical Endocrinology and Metabolism* 2004 **89** 3668–3676.
 - 44 Pacini F, Schlumberger M, Harmer C, Berg G, Cohen O, Duntas L, Jamar F, Jarzab B, Limbert E, Lind P, Reiners C, Sanchez Franco F, Smit J & Wiersinga W. Post surgical use of radioiodine (I-131) in patients with papillary and follicular thyroid cancer and the issue of remnant ablation. A consensus report. *European Journal of Endocrinology* 2005 **153** 651–659.
 - 45 Schroder PR, Haughen BR, Pacini F, Rainers C, Schlumberger M, Sherman SI, Cooper DS, Schuff KG, Breverman LE, Skarulis MC, Davis TF, Mazzaferri EL, Daniels GH, Ross DS, Luster M, Samuels MH, Wintraube BD, Ridgway EC & Ladenson PW. A comparison of short term changes in health related quality of life in thyroid carcinoma patients undergoing diagnostic evaluation with rhTSH compared to thyroid hormone withdrawal. *Journal of Clinical Endocrinology and Metabolism* 2006 **91** 878–884.
 - 46 Schlumberger M, Charbord P, Fragu P, Lumbruso J, Parmentier C & Tubiana M. Circulating thyroglobulin and thyroid hormones in patients with metastases of differentiated thyroid carcinoma: relationship to serum thyrotropin levels. *Journal of Clinical Endocrinology and Metabolism* 1980 **51** 513–519.
 - 47 Robbins RJ, Larson SM, Sinha N, Shaha A, Divgi C, Pentlow KS, Ghossein R & Tuttle RM. A retrospective review of the effectiveness of recombinant human TSH as a preparation for radioiodine thyroid remnant ablation. *Journal of Nuclear Medicine* 2002 **43** 1482–1488.
 - 48 Pacini F, Ladenson PW, Schlumberger M, Driedger A, Luster M, Kloos RT, Sherman S, Haughen B, Corone C, Molinaro E, Elisei R, Ceccarelli C, Pinchera A, Wahl RL, Lebouleux S, Ricard M, Yoo J, Bussaïdy NL, Delpassand E, Hanscheid H, Felbinger R, Lassmann M & Reiners C. Radioiodine ablation of thyroid remnants after preparation with recombinant human thyrotropin in differentiated thyroid carcinoma: results of an international, randomized, controlled study *Journal of Clinical Endocrinology and Metabolism* 2006 **91** 926–932.

- 49 Park HM, Park YH & Zhou XH. Detection of thyroid remnant/metastasis without stunning: an ongoing dilemma. *Thyroid* 1997 **7** 277–280.
- 50 Hilditch TE, Dempsey MF, Bolster AA, McMenemin RM & Reed NS. Self-stunning in thyroid ablation: evidence from comparative studies of diagnostic I-131 and I-123. *European Journal of Nuclear Medicine and Molecular Imaging* 2002 **29** 783–788.
- 51 Lassmann M, Luster M, Hanscheid H & Reiners C. Impact of ¹³¹I diagnostic activities on the biokinetics of thyroid remnants. *Journal of Nuclear Medicine* 2004 **45** 619–625.
- 52 Pluijmen MJ, Eustatia-Rutten C, Goslings BM, Stokkel MP, Arias AM, Diamant M, Romijn JA & Smit JW. Effects of low-iodide diet on postsurgical radioiodide ablation therapy in patients with differentiated thyroid carcinoma. *Clinical Endocrinology (Oxford)* 2003 **58** 428–435.
- 53 Fatourechi V, Hay ID, Mullan BP, Wiseman GA, Eghbali-Faotoreki GZ, Thorson LM & Gorman CA. Are posttherapy radioiodine scans informative and do they influence subsequent therapy of patients with differentiated thyroid cancer? *Thyroid* 2000 **10** 573–577.
- 54 Sherman SI, Tielens ET, Sostre S, Wharam MD Jr & Ladenson PW. Clinical utility of posttreatment radioiodine scans in the management of patients with thyroid carcinoma. *Journal of Clinical Endocrinology and Metabolism* 1994 **78** 629–634.
- 55 Hay ID, Bergstralh EJ, Goellner JR, Ebersold JR & Grant CS. Predicting outcome in papillary thyroid carcinoma: development of a reliable prognostic scoring system in a cohort of 1779 patients surgically treated at one institution during 1940 through 1989. *Surgery* 1993 **114** 1050–1057; discussion 1057–1058.
- 56 Hay ID, Thompson GB, Grant CS, Bergstralh EJ, Dvorak CE, Gorman CA, Maurer MS, McIver B, Mullan BP, Oberg AL, Powell CC, van Heerden JA & Goellner JR. Papillary thyroid carcinoma managed at the May Clinic during six decades (1940–1999): temporal trends in initial therapy and long-term outcome in 2444 consecutively treated patients. *World Journal of Surgery* 2002 **8** 879–885.
- 57 Byar DP, Green SB, Dor P, Williams ED, Colon J, van Gilse HA, Mayer M, Sylvester RJ & van Glabbeke M. A prognostic index for thyroid carcinoma. A study of the E.O.R.T.C. Thyroid Cancer Cooperative Group. *European Journal of Cancer* 1979 **15** 1033–1041.
- 58 Tenvall J, Bjorklund A, Moller T, Ranstam J & Akerman M. Is the EORTC prognostic index of thyroid cancer valid in differentiated thyroid carcinoma? Retrospective multivariate analysis of differentiated thyroid carcinoma with long follow-up. *Cancer* 1986 **57** 1405–1414.
- 59 Saha AR, Loree TR & Shah JP. Prognostic factors and risk group analysis in follicular carcinoma of the thyroid. *Surgery* 1995 **118** 1131–1136; discussion 1136–1138.
- 60 Sherman SI, Brierley JD, Sperling M, Ain KB, Bigos ST, Cooper DS, Haugen BR, Ho M, Klein I, Landenson PW, Robbins J, Ross DS, Specker B, Taylor T & Maxon HR. Prospective multicenter study of thyroid carcinoma treatment: initial analysis of staging and outcome. National Thyroid Cancer Treatment Cooperative Study Registry Group. *Cancer* 1998 **83** 1012–1021.
- 61 Links TP, van Tol KM, Jager PL, Plukker JThM, Piers DA, Boezen HM, Dullaart RPF, deVries EGE & Sluiter WJ. Life expectancy in differentiated thyroid cancer: a novel approach to survival analysis. *Endocrine-related Cancer* 2005 **12** 272–280.
- 62 Wittekind C, Compton CC, Greene FL & Sobin LH. TNM residual tumor classification revisited. *Cancer* 2002 **94** 2511–2516.
- 63 Cooper DS, Specker B, Ho M, Sperling M, Ladenson PW, Ross DS, Ain KB, Bigos ST, Brierley JD, Haughen BR, Klein I, Robbins J, Sherman SI, Taylor T & Maxon HR. Thyrotropin suppression and disease progression in patients with differentiated thyroid cancer: results from the National Thyroid Cancer Treatment Cooperative Registry. *Thyroid* 1998 **8** 737–744.
- 64 McGriff NJ, Csako G, Gourgiotis L, Lori CG, Pucino F & Sarlis NJ. Effects of thyroid hormone suppression therapy on adverse clinical outcomes in thyroid cancer. *Annals of Medicine* 2002 **34** 554–564.
- 65 Baudin E, Do Cao C, Cailleux AF, Leboulleux S, Travagli JP & Schlumberger M. Positive predictive value of serum thyroglobulin levels, measured during the first year of follow-up after thyroid hormone withdrawal, in thyroid cancer patients. *Journal of Clinical Endocrinology and Metabolism* 2003 **88** 1107–1111.
- 66 Schlumberger M, Berg G, Cohen O, Duntas L, Jamar F, Jarzab B, Lambert E, Lind P, Pacini F, Reiners C, Franco FS, Toft A & Wiersinga WM. Follow-up of low-risk patients with differentiated thyroid carcinoma: a European perspective. *European Journal of Endocrinology* 2004 **150** 105–112.
- 67 Biondi B, Filetti S & Schlumberger M. Thyroid-hormone therapy and thyroid cancer: a reassessment. *Nature Clinical Practice Endocrinology and Metabolism* 2005 **1** 32–40.
- 68 Horne MK 3rd, Singh KK, Rosenfeld KG, Wesley R, Skarulis MC, Merryman PK, Cullinane A, Costello R, Patterson A, Eggerman T, Bernstein DM, Pucino F & Csako G. Is thyroid hormone suppression therapy prothrombotic? *Journal of Clinical Endocrinology and Metabolism* 2004 **89** 4469–4473.
- 69 Feldt-Rasmussen U, Profilis C, Colinet E, Black E, Bornet H, Bourdoux P, Carayon P, Ericsson UB, Koutras DA, Lamas de Leon L, DeNayer P, Pacini F, Palumbo G, Santos A, Schlumberger M, Seidel C, Van Herle AJ & De Vijlder JJM. Human thyroglobulin reference material (CRM 457). 1st part: assessment of homogeneity, stability and immunoreactivity. *Annales de Biologie Clinique Paris* 1996 **54** 337–342.
- 70 Feldt-Rasmussen U, Profilis C, Colinet E, Black E, Bornet H, Bourdoux P, Carayon P, Ericsson UB, Koutras DA, Lamas de Leon L, DeNayer P, Pacini F, Palumbo G, Santos A, Schlumberger M, Seidel C, Van Herle AJ & De Vijlder JJM. Human thyroglobulin reference material (CRM 457). 2nd part: physicochemical characterization and certification. *Annales de Biologie Clinique Paris* 1996 **54** 343–348.
- 71 Chiovato L, Latrofa F, Braverman LE, Pacini F, Capezzone M, Masserini L, Grasso L & Pinchera A. Disappearance of humoral thyroid autoimmunity after complete removal of thyroid antigens. *Annals of Internal Medicine* 2003 **139** 346–351.
- 72 Cailleux AF, Baudin E, Travagli JP, Ricard M & Schlumberger M. Is diagnostic iodine-131 scanning useful after total thyroid ablation for differentiated thyroid carcinoma? *Journal of Clinical Endocrinology and Metabolism* 2000 **85** 175–178.
- 73 Pacini F, Capezzone M, Elisei R, Ceccarelli C, Taddei D & Pinchera A. Diagnostic 131-iodine whole-body scan may be avoided in thyroid cancer patients who have undetectable stimulated serum Tg levels after initial treatment. *Journal of Clinical Endocrinology and Metabolism* 2002 **87** 1499–1501.
- 74 Pacini F, Molinaro E, Castagna MG, Agate L, Elisei R, Ceccarelli C, Lippi F, Taddei D, Grasso L & Pinchera A. Recombinant human thyrotropin-stimulated serum thyroglobulin combined with neck ultrasonography has the highest sensitivity in monitoring differentiated thyroid carcinoma. *Journal of Clinical Endocrinology and Metabolism* 2003 **88** 3668–3673.
- 75 Torlontano M, Attard M, Crocetti U, Tumino S, Bruno R, Costante G, D'Azzo G, Meringolo D, Ferretti E, Sacco R, Arturi F & Filetti S. Follow-up of low risk patients with papillary thyroid cancer: role of neck ultrasonography in detecting lymph node metastases. *Journal of Clinical Endocrinology and Metabolism* 2004 **89** 3402–3407.
- 76 Pacini F, Molinaro E, Lippi F, Castagna MG, Agate L, Ceccarelli C, Taddei D, Elisei R, Capezzone M & Pinchera A. Prediction of disease status by recombinant human TSH-stimulated serum Tg in the postsurgical follow-up of differentiated thyroid carcinoma. *Journal of Clinical Endocrinology and Metabolism* 2001 **86** 5686–5690.
- 77 Schlumberger M, Arcangioli O, Piekarski JD, Tubiana M & Parmentier C. Detection and treatment of lung metastases of differentiated thyroid carcinoma in patients with normal chest X-rays. *Journal of Nuclear Medicine* 1988 **29** 1790–1794.

- 78 Pineda JD, Lee T, Ain K, Reynolds JC & Robbins J. Iodine-131 therapy for thyroid cancer patients with elevated thyroglobulin and negative diagnostic scan. *Journal of Clinical Endocrinology and Metabolism* 1995 **80** 1488–1492.
- 79 Pacini F, Agate L, Elisei R, Capezzone M, Ceccarelli C, Lippi F, Molinaro E & Pinchera A. Outcome of differentiated thyroid cancer with detectable serum thyroglobulin and negative diagnostic ¹³¹I whole body scan: comparison of patients treated with high ¹³¹I activities versus untreated patients. *Journal of Clinical Endocrinology and Metabolism* 2001 **86** 4092–4097.
- 80 Luster M, Lippi F, Jarzab B, Perros P, Lassmann M, Reiners C & Pacini F. rhTSH-aided radioiodine ablation and treatment of differentiated thyroid carcinoma: a comprehensive review. *Endocrine-related Cancer* 2005 **12** 49–64.
- 81 Haugen BR, Pacini F, Reiners C, Schlumberger M, Ladenson PW, Sherman SI, Cooper DS, Graham KE, Braverman LE, Skarulis MC, Davies TF, DeGroot LJ, Mazzaferri EL, Daniels GH, Ross DS, Luster M, Samuels MH, Becher DV, Maxon HR, Cavalieri RR, Spencer CA, McEllin K, Weintraub BD & Ridgway EC. A comparison of recombinant human thyrotropin and thyroid hormone withdrawal for the detection of thyroid remnant or cancer. *Journal of Clinical Endocrinology and Metabolism* 1999 **84** 3877–3885.
- 82 Driedger AA & Kotowycz N. Two cases of thyroid carcinoma that were not stimulated by recombinant human thyrotropin. *Journal of Clinical Endocrinology and Metabolism* 2004 **89** 585–590.
- 83 Wang W, Macapinlac H, Larson SM, Yeh SD, Akhurst T, Finn RD, Rosai J & Robbins RJ. [¹⁸F]-2-fluoro-2-deoxy-D-glucose positron emission tomography localizes residual thyroid cancer in patients with negative diagnostic ¹³¹I whole body scans and elevated serum thyroglobulin levels. *Journal of Clinical Endocrinology and Metabolism* 1999 **84** 2291–2302.
- 84 Helal BO, Merlet P, Toubert ME, Franc B, Schwartz C, Gauthier-Koelesnikov H, Prigent A & Syrota A. Clinical impact of ¹⁸F-FDG PET in thyroid carcinoma patients with elevated thyroglobulin levels and negative ¹³¹I scanning results after therapy. *Journal of Nuclear Medicine* 2001 **42** 1464–1469.
- 85 Chin BB, Patel P, Cohade C, Ewertz M, Wahl R & Ladenson P. Recombinant human thyrotropin stimulation of fluoro-D-glucose positron emission tomography uptake in well-differentiated thyroid carcinoma. *Journal of Clinical Endocrinology and Metabolism* 2004 **89** 91–95.
- 86 Nahas Z, Goldenberg D, Fakhry C, Ewertz M, Zeiger M, Ladenson PW, Wahl R & Tufano RP. The role of positron emission tomography/computed tomography in the management of recurrent papillary thyroid carcinoma. *Laryngoscope* 2005 **115** 237–243.
- 87 Robbins RJ, Wan Q, Grewal RK, Reibke R, Gonen M, Strauss HW, Tuttle RM, Drucker W & Larson SM. Real-time prognosis for metastatic thyroid carcinoma based on FDG-PET scanning. *Journal of Clinical Endocrinology and Metabolism* 2006 **91** 498–505.
- 88 Schlumberger M, Pacini F, Wiersinga WM, Toft A, Smit JW, Sanchez Franco F, Lind P, Lambert E, Jarzab B, Jamar F, Duntas L & Cohen G. Follow-up and management of differentiated thyroid carcinoma: European perspective in clinical practice. *European Journal of Endocrinology* 2004 **151** 539–548.
- 89 Schlumberger M, Ricard M & Pacini F. Clinical use of recombinant human TSH in thyroid cancer patients. *European Journal of Endocrinology* 2000 **143** 557–563.
- 90 Mazzaferri EL, Robbins RJ, Spencer CA, Braverman LE, Pacini F, Wartofsky L, Haugen BR, Sherman SI, Cooper DS, Braunstein GD, Lee S, Davies TF, Arafah BM, Ladenson PW & Pinchera A. A consensus report of the role of serum thyroglobulin as a monitoring method for low-risk patients with papillary thyroid carcinoma. *Journal of Clinical Endocrinology and Metabolism* 2003 **88** 1433–1441.
- 91 Leeper RD. The effect of ¹³¹I therapy on survival of patients with metastatic papillary or follicular thyroid carcinoma. *Journal of Clinical Endocrinology and Metabolism* 1973 **36** 1143–1152.
- 92 Beierwaltes WH, Nishiyama RH, Thompson NW, Copp JE & Kubo A. Survival time and 'cure' in papillary and follicular thyroid carcinoma with distant metastases: statistics following University of Michigan therapy. *Journal of Nuclear Medicine* 1982 **23** 561–568.
- 93 Bernier MO, Leenhardt L, Hoang C, Aurengo A, Mary JY, Menegaux F, Enkaoua E, Turpin G, Chiras J, Saillant G & Hejblum G. Survival and therapeutic modalities in patients with bone metastases of differentiated thyroid carcinomas. *Journal of Clinical Endocrinology and Metabolism* 2001 **86** 1568–1573.
- 94 Pacini F, Cetani F, Miccoli P, Mancusi F, Ceccarelli C, Lippi F, Martino E & Pinchera A. Outcome of 309 patients with metastatic differentiated thyroid carcinoma treated with radioiodine. *World Journal of Surgery* 1994 **18** 600–604.
- 95 Pons F, Carrio I, Estorch M, Ginjaume M, Pons J & Milian R. Lithium as an adjuvant of iodine-131 uptake when treating patients with well-differentiated thyroid carcinoma. *Clinical Nuclear Medicine* 1987 **12** 644–647.
- 96 Koong SS, Reynolds JC, Movius EG, Keenan AM, Ain KB, Lakshmanan MC & Robbins J. Lithium as a potential adjuvant to ¹³¹I therapy of metastatic, well differentiated thyroid carcinoma. *Journal of Clinical Endocrinology and Metabolism* 1999 **84** 912–916.
- 97 Zettinig G, Fueger BJ, Passler C, Kaserer K, Pirich C, Dudczak R & Niederle B. Long-term follow-up of patients with bone metastases from differentiated thyroid carcinoma – surgery or conventional therapy? *Clinical Endocrinology (Oxford)* 2002 **56** 377–382.
- 98 Pittas AG, Adler M, Fazzari M, Tickoo S, Rosai J, Larson SM & Robbins RJ. Bone metastases from thyroid carcinoma: clinical characteristics and prognostic variables in one hundred forty-six patients. *Thyroid* 2000 **10** 261–268.
- 99 Schlumberger M, Challeton C, De Vathaire F, Travagli J-P, Gardet P, Lumbroso J-D, Francese C, Fontaine F, Ricard M & Parmentier C. Radioactive iodine treatment and external radiotherapy for lung and bone metastases from thyroid carcinoma. *Journal of Nuclear Medicine* 1996 **37** 598–605.
- 100 Marcocci C, Pacini F, Elisei R, Schipani E, Ceccarelli C, Miccoli P, Arganini M & Pinchera A. Clinical and biological behaviour of bone metastases from differentiated thyroid carcinoma. *Surgery* 1989 **106** 960.
- 101 McWilliams RR, Giannini C, Hay ID, Atkinson JL, Stafford SL & Buckner JC. Management of brain metastases from thyroid carcinoma: a study of 16 pathologically confirmed cases over 25 years. *Cancer* 2003 **98** 356–362.
- 102 Mandel SJ & Mandel L. Radioactive iodine and the salivary glands. *Thyroid* 2003 **13** 265–271.
- 103 Nakada K, Ishibashi T, Takei T, Hirata K, Shinohara K, Katoh S, Zhao S, Tamaki N, Noguchi Y & Noguchi S. Does lemon candy decrease salivary gland damage after radioiodine therapy for thyroid cancer? *Journal of Nuclear Medicine* 2005 **46** 261–266.
- 104 Ceccarelli C, Battisti P, Gasperi M, Fantuzzi E, Pacini F, Gualdrini G, Pierantoni MR, Luciani A, Djokich D & Pinchera A. Radiation dose to the testes after ¹³¹I therapy for ablation of post-surgical thyroid remnants in patients with differentiated thyroid cancer. *Journal of Nuclear Medicine* 1999 **40** 1716–1721.
- 105 Pacini F, Gasperi M, Fugazzola L, Ceccarelli C, Lippi F, Centoni R, Martino E & Pinchera A. Testicular function in patients with differentiated thyroid carcinoma treated with radioiodine. *Journal of Nuclear Medicine* 1994 **35** 1418–1422.
- 106 Schlumberger M, De Vathaire F, Ceccarelli C, Delisle MJ, Francese C, Couette JE, Pinchera A & Parmentier C. Exposure to radioactive iodine-131 for scintigraphy or therapy does not preclude pregnancy in thyroid cancer patients. *Journal of Nuclear Medicine* 1996 **37** 606–612.
- 107 Ceccarelli C, Benicivelli W, Morciano D, Pinchera A & Pacini F. ¹³¹I therapy for differentiated thyroid cancer leads to an earlier onset of menopause: results of a retrospective study. *Journal of Clinical Endocrinology and Metabolism* 2001 **86** 3512–3515.
- 108 Rubino C, de Vathaire F, Dottorini ME, Hall P, Schwartz C, Couette JE, Dondon MG, Abbas MT, Langlois C & Schlumberger M. Second primary malignancies in thyroid cancer patients. *British Journal of Cancer* 2003 **89** 1638–1644.

- 109 de Vathaire F, Schlumberger M, Delisle MJ, Francese C, Challeton C, de la Genardiere E, Meunier F, Parmentier C, Hill C & Sancho-Garnier H. Leukaemias and cancers following iodine-131 administration for thyroid cancer. *British Journal of Cancer* 1997 **75** 734–739.
- 110 Ford D, Giridharan S, McConkey C, Hartley A, Brammer C, Watkinson JC & Glaholm J. External beam radiotherapy in the management of differentiated thyroid cancer. *Clinical Oncology (Royal College of Radiology)* 2003 **15** 337–341.
- 111 Mazzarotto R, Cesaro MG, Lora O, Rubello D, Casara D & Sotti G. The role of external beam radiotherapy in the management of differentiated thyroid cancer. *Biomedicine and Pharmacotherapy* 2000 **54** 345–349.
- 112 Droz JP, Schlumberger M, Rougier P, Ghosn M, Gardet P & Parmentier C. Chemotherapy in metastatic nonanaplastic thyroid cancer: experience at the Institut Gustave-Roussy. *Tumori* 1990 **76** 480–483.
- 113 Pacini F, Vitti P, Martino E, Giani C, Bambini G, Pinchera A & Bascheri L. Treatment of refractory thyroid cancer with adriamycin. *Drugs Under Experimental and Clinical Research* 1984 **10** 911–916.
- 114 Haugen BR. Management of the patient with progressive radioiodine non-responsive disease. *Seminars in Surgical Oncology* 1999 **16** 34–41.
- 115 Santini F, Bottici V, Elisei R, Montanelli L, Mazzeo S, Basolo F, Pinchera A & Pacini F. Cytotoxic effects of carboplatinum and epirubicin in the setting of an elevated serum thyrotropin for advanced poorly differentiated thyroid cancer. *Journal of Clinical Endocrinology and Metabolism* 2002 **87** 4160–4165.
- 116 Braga-Brasaria M & Ringel MD. Beyond radioiodine: a review of potential new therapeutic approaches for thyroid cancer. *Journal of Clinical Endocrinology and Metabolism* 2003 **88** 1947–1960.

Received 10 February 2006

Accepted 3 March 2006